

Smile Design Using a Combination of Minimally Invasive Porcelain Veneers and All-Ceramic Crowns

By Howard E. Strassler, DMD, FADM, FAGD

Understanding how to achieve an esthetic match between different thicknesses of porcelain when combining minimally invasive porcelain veneers and all-ceramic crowns is a significant challenge when restoring multiple teeth with different restoration types in the esthetic zone. The case presented demonstrates the use of a hybrid approach combining two different restoration types within the same family of restorative materials—porcelain veneers and crowns—and achieving a highly esthetic result.

Case Report

A 28-year-old man presented to the dental school with a desire to improve his smile. A clinical evaluation revealed an endodontically stained tooth No. 9 that had been traumatized and fractured 15 years previously, but never required endodontic treatment. At the time of presentation, it had an obliterated root canal, as well as an incisal edge fracture of tooth No. 8. Both teeth had been restored with direct composite resin. Also, there was spacing between the maxillary lateral and maxillary central incisors bilaterally (Figure 1). The patient wanted to have a “whiter smile,” the spaces closed between his front teeth, and a more esthetic appearance of the maxillary central incisors. He had a past dental history of a 4-week

course of at-home bleaching 6 months previously for both maxillary and mandibular arches.

Matching crowns to porcelain veneers can be challenging. Porcelain at different thicknesses has a different optical appearance and properties due to how light passes through the porcelain.^{1,2} In those circumstances when teeth in the esthetic zone will have a mixture of ceramic crowns and porcelain veneers, it is recommended that a slightly more opaque porcelain be used to neutralize the optical differences in a thin porcelain veneer and a thicker porcelain crown.³ In these cases, the use of feldspathic porcelain offers the ceramist better control over porcelain opacity, color, and shade because of how the porcelain restoration is fabricated.^{4,5} After discussing treatment alternatives including bleaching, crown placement, direct composite resin bonding, and minimally invasive porcelain veneers, the patient decided to choose the most conservative treatment choice with the best esthetic result. It was decided that because of tooth alignment and shape and the preexisting restorations on teeth Nos. 8 and 9, an acceptable esthetic result could be achieved with minimally invasive porcelain veneers for teeth Nos. 6, 7, 10, and 11 and all-ceramic crowns for teeth Nos. 8 and 9 could be fabricated with feldspathic porcelain. The patient approved a diagnostic wax-up.

A minimally invasive preparation was done for the maxillary canines and lateral incisors with the preparation over the incisal edges with a definitive finish line margin on the lingual surfaces. Both teeth Nos. 8 and 9 were prepared for all-ceramic crowns (Figure 2). An impression was made

with a fast-setting, regular-body vinyl polysiloxane impression material (Take 1[®] Advanced™ Superfast, Kerr Dental) in a bite-impression tray. The bite-impression technique provides the laboratory with an accurate impression of the teeth to be restored, the opposing arch, and bite registration. This

technique eliminates the guesswork for the laboratory in articulating casts and guarantees accurate articulation of casts.⁶ The laboratory authorization was completed describing the purpose of the veneers and crowns, including alignment, incisal widths and lengths, shade desired, and surface texture for

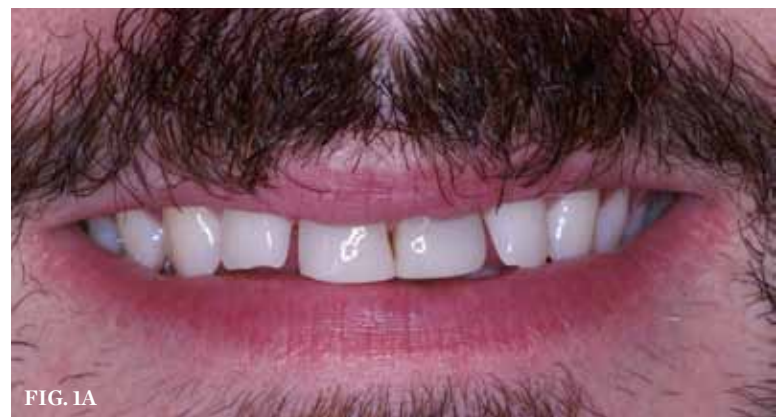

FIG. 1A

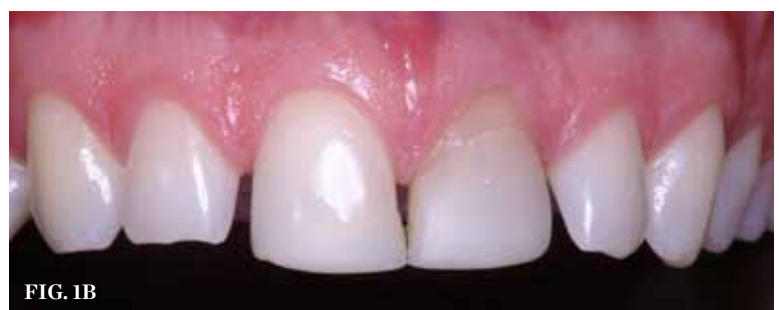

FIG. 1B

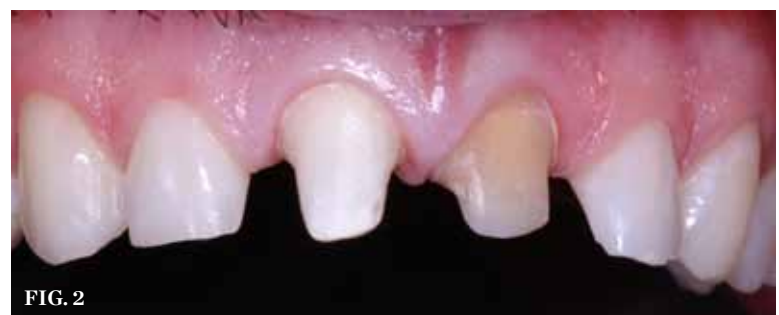

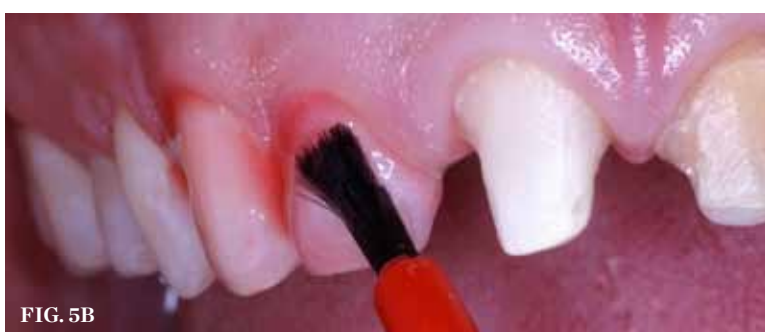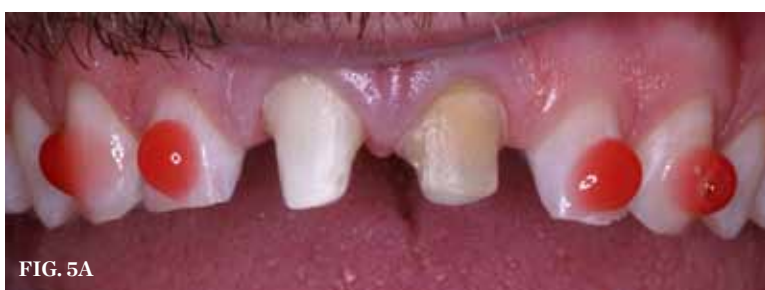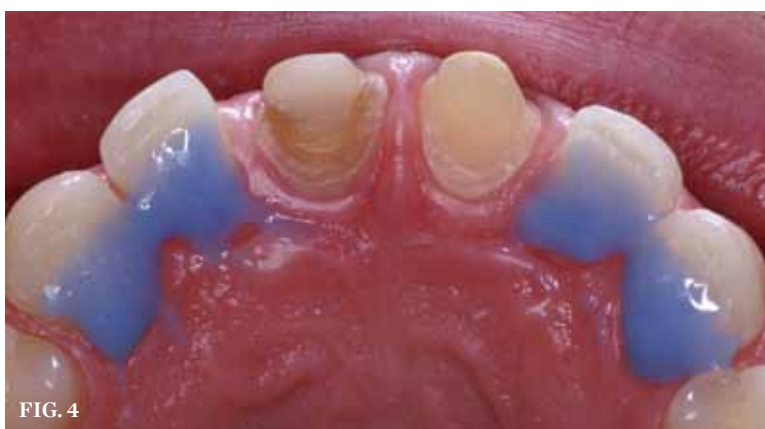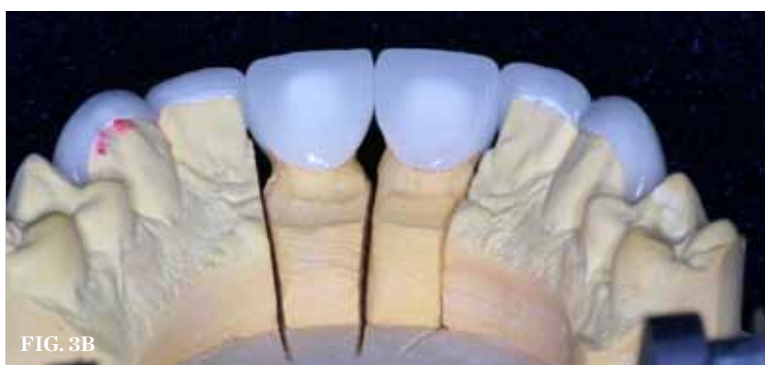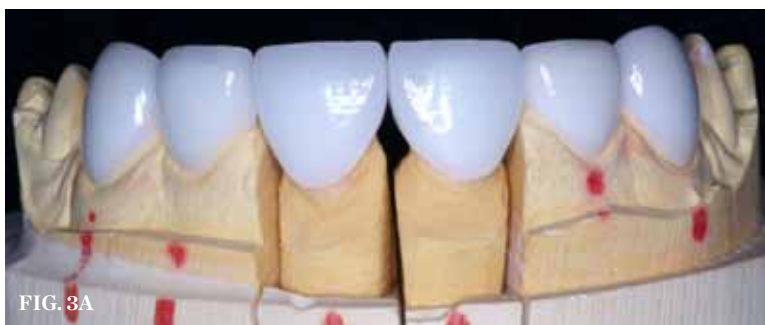FIG. 2

(1.) Preoperative condition: (A) smile view; (B) retracted view. (2.) Minimally invasive veneer preparations of teeth Nos. 6, 7, 10, and 11 and crown preparations of teeth Nos. 8 and 9.

HOWARD E. STRASSLER,
DMD, FADM, FAGD

Professor and Director of Operative Dentistry
Department of Endodontics, Prosthodontics and
Operative Dentistry
University of Maryland Dental School
Baltimore, Maryland

CASE REPORT



(3.) Restorations returned from the laboratory. Note the difference in the appearance of the porcelain of the crown and veneers due to porcelain thickness. (A) facial view; (B) lingual view. (4.) Lingual block-out of enamel surfaces with a gingival barrier resin. (5.) Etching intra-enamel veneer preparations for 15 to 30 seconds. (A) initial application of phosphoric acid etchant; (B) using a brush to paint phosphoric-acid etchant over the enamel surfaces to be bonded and restored.

the facial surfaces. A digital photograph of the preparations was included to show the ceramist the endodontic staining of tooth No. 9, and the diagnostic wax-up was included with the impressions as well. Because of the optical property differences between a thicker crown and thin veneer, a 35% opacity for the porcelain was requested for the veneers and crowns. Provisional crowns were fabricated for teeth Nos. 8 and 9 using a prefabricated acrylic resin shell that was relined and adjusted chairside. Teeth Nos. 6, 7, 10, and 11 did not require provisional restorations because they were minimally reshaped.

The laboratory returned the restorations (Figure 3). Because of the difference in thicknesses between the crowns and the veneers, there was an optical difference in the appearance of the tooth shade. The crown and veneers were verified on the working cast. The provisional crowns were removed and the teeth and preparations of all surfaces to be bonded were cleaned with a water-pumice paste using a disposable prophylaxis angle. The interproximal surfaces of the teeth being veneered were cleaned using diamond finishing strips. To make excess composite cement clean up easier and to exclude etchant from the lingual surfaces of the veneer preparations, a blue flowable resin used for gingival protection for 1-hour bleaching was applied to the lingual surfaces so as not to interfere with veneer placement (Figure 4). The teeth were then wetted with water and the veneers and crowns were tried on the teeth to verify fit and esthetic shape. Color try-in was not necessary for this case because of the porcelain opacity.

Surface Treatments

The bonding of porcelain to the tooth surfaces is a multistage technique. It requires a variety of different reagents to optimize the bond to the porcelain and tooth. The intaglio internal surfaces of all the porcelain restorations were etched in the laboratory with hydrofluoric acid. At chairside, the etched intaglio was treated with a silane porcelain primer (from the NX3 Nexus[®] kit, Kerr Dental) for 30 seconds and air-dried. A fifth-generation resin adhesive (OptiBond[®] Solo Plus[™], Kerr Dental) was then applied to the internal porcelain surfaces and a gentle air stream was blown over the surface to air thin the adhesive and evaporate

the solvent from the adhesive. Do not light-cure the adhesive on the veneer. Dual-cure composite resin cements can be used for cementation of all types of indirect restorations but, due to potential problems with color stability, it is recommended that translucent all-ceramic restorations—such as all-ceramic crowns and veneers—be placed with light-cure composite cements.^{7,8} When using light-cured-only composite resin cements with all-ceramic veneers or crowns, the light-curing time should be increased when polymerizing through porcelain thicknesses of 0.5 mm to 2 mm.⁹ For this case, a light-cured resin cement, NX3 Nexus[®] Third Generation (Kerr) was selected. NX3 Nexus contains both a light-cure veneer resin cement with a color-matched try-in paste and a dual-cure, auto-mixing resin cement. The light-cure cement has superior color stability for long-term esthetics, as well as excellent adhesion to enamel, dentin, and ceramics. Because an opaque porcelain was used, it was decided not to use the try-in paste to evaluate color. The light-cure resin cement was placed into each veneer and crown. The restorations were placed aside in a light-safe box before light-cure resin-cement placement.

For this case and based on the current evidence when placing porcelain veneers, an etch-and-rinse technique was used with the fifth-generation adhesive, OptiBond Solo Plus. While the restorations were being surface-treated by the chairside assistant for bonding, the teeth to be restored were etched with a 37% phosphoric acid gel that could be easily painted over the tooth surfaces. This etchant gel is less viscous than most etchants, so it is easier to paint over the tooth surfaces. Because two different types of tooth structure were going to be etched, a two-stage etching was done. First the veneer preparations were etched for 15 to 30 seconds. This author has found that using a less viscous etchant, applying it to the facial surfaces in bulk, and then painting it over the surfaces with a brush is more effective (Figure 5). The etchant was rinsed from the intra-enamel veneer preparations for 10 seconds with an air-water spray. When dried, the enamel had a frosty appearance. Then the crown preparations (dentin) were etched for 10 seconds (Figure 6) and then rinsed for 10 seconds with an air-water spray. It is important not to

CASE REPORT

over-etch dentin because it can have a negative impact on adhesion.

Because the adhesion is to both dentin and enamel for this case, the adhesive was placed to be tooth-structure specific. The dentin surface of the crown preparations were lightly wetted with water using a damp microapplicator, leaving the etched dentin with a slightly glossy appearance (Figure 7). A resin adhesive (OptiBond Solo Plus) was applied with a brush to the crown preparations and all etched surfaces of the veneer preparations but not light-cured until the veneers and crowns were placed (Figure 8).

Porcelain Restoration Placement

The four veneers and both ceramic crowns were bonded to place using a multiple placement no-matrix technique that has been described by Putter and associates.^{10,11} This technique has

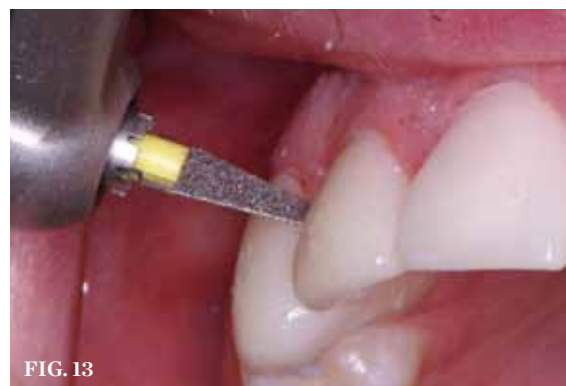
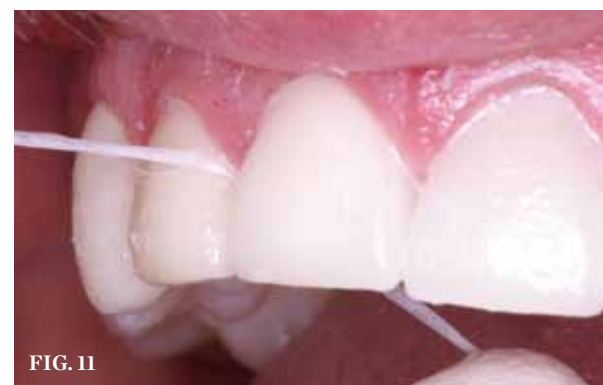
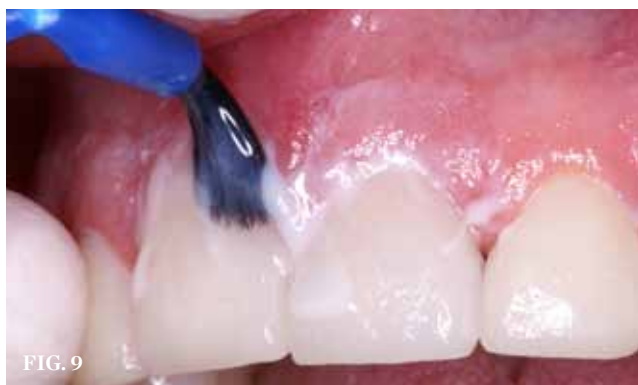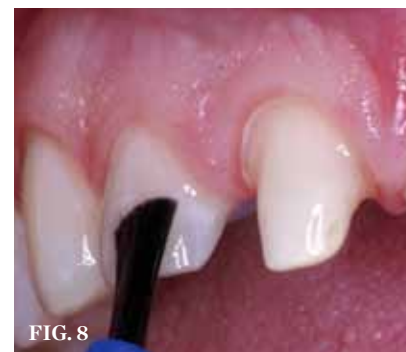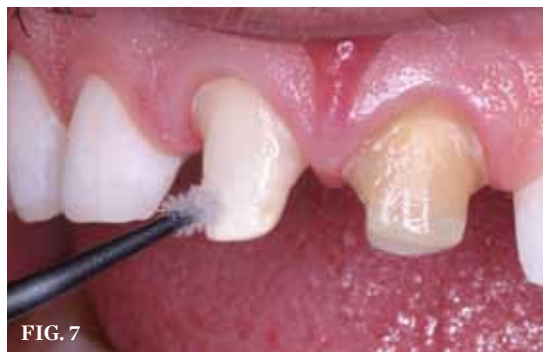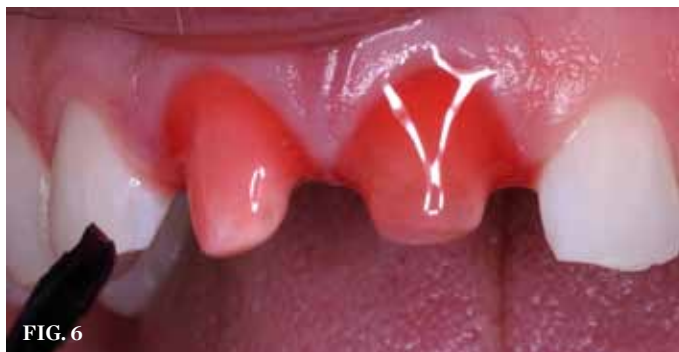greatly simplified the placement of porcelain veneers.¹² In other techniques, veneers are bonded to place either one or two at a time. When this is done, the composite resin cement must be finished at the proximal margins before the seating of adjacent veneers. This can be problematic. In some cases finishing the interproximal margins of porcelain veneers can cause gingival hemorrhage that can interfere with subsequent continued bonding of the adjacent veneers. The veneers were placed simultaneously on the teeth along with the ceramic crowns. As each veneer was placed, the back end of the brush was used to fully seat the veneers. The same was done with the crowns.

Complete seating of the restorations was verified visually. Excess resin cement was removed using a brush wetted with adhesive bonding resin (Optibond Solo Plus) (Figure 9). This technique assures that the resin cement will be

at the margins of the veneers. Each veneer was tack cured for 5 seconds with a 2-mm light guide tacking tip using a quartz-halogen curing light (Optilux® 501, Kerr Demetron); each crown was cured for 10 seconds with the tip oriented in the middle of the facial surface of each veneer and crown (Figure 10). Using a narrow-diameter light guide as a tacking tip for a short burst of time allows for easy clean up of excess resin cement from around the veneer and crown margins. Because no matrix strips are used for this simultaneous technique, floss was gently passed between the proximal surfaces to allow for easy interproximal clean up of excess cement (Figure 11). Additional excess resin cement was removed before further light-curing. The veneers and crowns were then light-cured one at a time on the facial and lingual surfaces for 30 seconds with a curved 13-mm wide light guide (Figure 12). Additional

time for light-curing is necessary because the light must penetrate the thickness of the veneers and crowns.⁹

Removal of excess resin cement and marginating the porcelain to remove any potential ledges is critical to clinical success when placing bonded porcelain restorations. Finishing and polishing of the margins was accomplished with fine finishing diamonds and burs. The contacts were then opened up for access using a diamond strip with serrations. It is not necessary to open all contact areas at the placement appointment. In some cases, the more difficult to access proximal contacts can be more easily managed and opened up at a follow-up appointment. Tooth movement during function loosens those tight contacts to allow for easier access at the next appointment. Interproximal finishing was accomplished with diamond strips. The removal of resin cement and slight recontouring of the interproximal



(6.) Separate etching of the crown preparations with phosphoric-acid etchant for 10 to 15 seconds. (7.) Moisturizing the dentin of the crown preparations with a moist micro-applicator. (8.) Application of a fifth-generation adhesive to the tooth preparations. (9.) Excess cement was cleared away with a brush wetted with adhesive before the tacking cure. (10.) Tacking the veneers and crowns to place with a 2-mm wide light guide for 5 seconds. (11.) Passing floss between the contacts before complete light-curing allows for easier access to the contact areas after light-curing. (12.) Each restoration was light-cured on the facial and lingual surfaces with a 13-mm curved light guide for 30 seconds. (13.) Gingival interproximal finishing with a reciprocating handpiece and flat-bladed, safe-sided diamond tips.

gingival surfaces was accomplished with a reciprocating handpiece that is the same dimensions as a disposable prophylaxis angle and fits on the straight nose cone of a slow-speed handpiece using a thin, flat-bladed, safe-sided diamond tip (Figure 13). Use of a thin diamond bur in the gingival interproximal areas with a high-speed handpiece is contraindicated because one can notch the veneers in these areas, leaving an esthetically unsatisfactory restoration. When compared to the preoperative smile, the completed minimally invasive porcelain veneers and all-ceramic crowns provide for a highly esthetic result with which the patient was thoroughly pleased (Figure 14). At 2 years, the porcelain restorations bonded with Optibond Solo Plus and NX3 Nexus light-cure resin cement restorations are functioning satisfactorily (Figure 15).

Conclusion

All-ceramic veneers and crowns bonded with light-cured composite resin cement provide for a clinically successful treatment modality to cosmetically restore teeth with unesthetic appearances. One challenge when using different types of ceramic restorations of different thicknesses is understanding how to control porcelain color to get a match when the restorations are different thicknesses. This article demonstrates a successful technique to manage these hybrid cases.

References

1. Powers JL. Optical, thermal, and electrical properties. *Craig's Restorative Dental Materials*. 12th Edition. Mosby Elsevier. 2006;27-50.
2. Powers JL. Ceramics. *Craig's Restorative Dental Materials*. 12th Edition. Mosby

Elsevier. 2006;443-464.

3. Strassler HE, Cloutier PC. A new fiber post for esthetic dentistry. *Compend Contin Dent Educ*. 2003;24:742-753.
4. McLaren EA, Whiteman YY. Ceramics: rationale for material selection. *Compend Contin Dent Educ*. 2010;31:666-679.
5. McLaren EA, LeSage B. Feldspathic veneers: what are their indications? *Compend Contin Dent Educ*. 2011;32:44-49.
6. Cevhan JA, Johnson GH, Lepe X, Phillips KM. A clinical study comparing the three-dimensional accuracy of a working die generated from two dual-arch trays and a complete-arch custom tray. *J Prosthet Dent*. 2003;90:228-234.
7. Nathanson D, Banasr F. Color stability of resin cements—an in vitro study. *Pract Proced Aesthet Dent*. 2002;14:449-455.
8. Hekimoglu C, Anil N, Etikan I. Effect of accelerated aging on the color stability of cemented laminate veneers. *Int J Prosthodont*. 2000;13:29-33.
9. Powers JM, Sakaguchi RL. Cements. In: *Craig's Restorative Dental Materials*. 12th Edition. 2006;480-511.
10. Putter H, Strassler HE. An instrument for opening contact areas for interproximal finishing. *J Esthet Dent*. 1989;1:194-197.
11. Putter H, Ibsen RL. Simultaneous placement of multiple porcelain veneers. *J Esthet Dent*. 1990;2:67-69.
12. Strassler HE. Minimally invasive porcelain veneers: indications for a conservative treatment esthetic dentistry modality. *Gen Dent*. 2007;55:686-696.

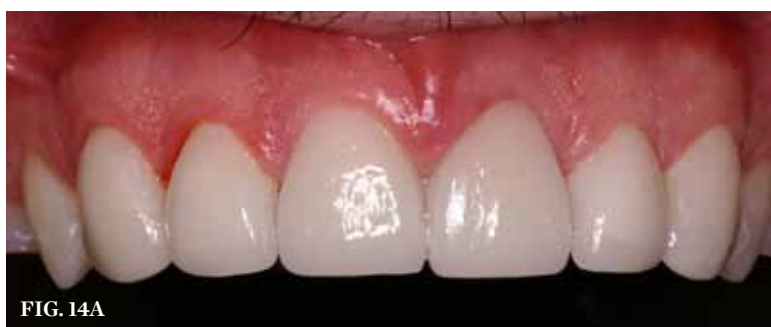

FIG. 14A

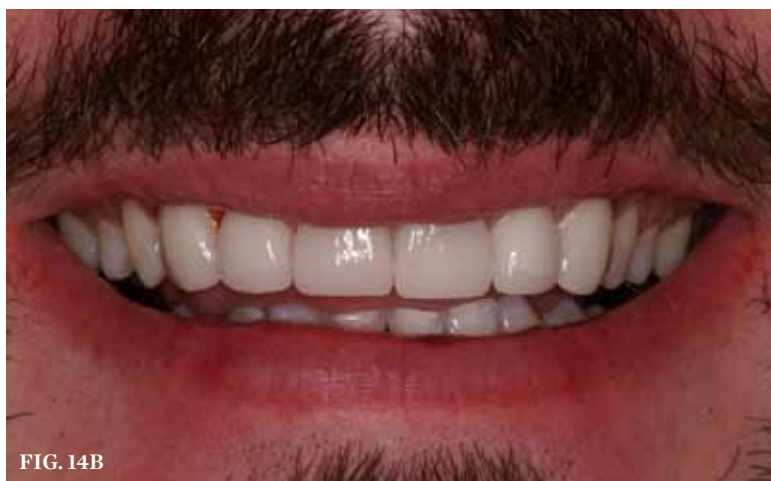

FIG. 14B

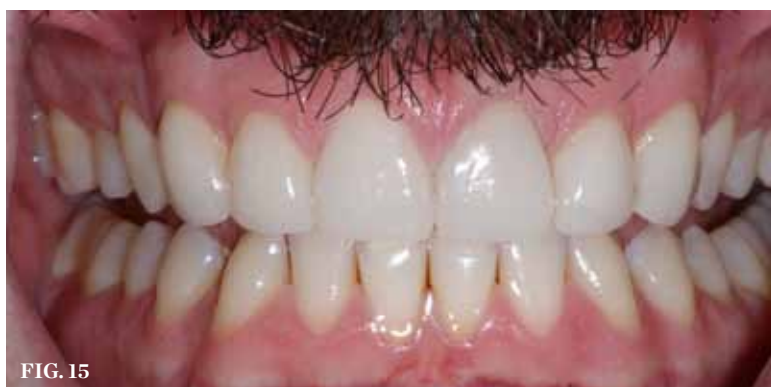

FIG. 15

(14.) Completed restorations accomplished the smile the patient desired. (A) retracted view; (B) smile view. (15.) The 2-year recall.